

Battery Swallowing: Original image

Battery

Kayıpmaz Afşin Emre, Taneri Birand, Kavalci Cemil

Department of Emergency, Faculty of Medicine, Baskent University, Ankara, Turkey

A 5-year-old male patient presented to our emergency department complaint of accidentally swallowing a battery one hours ago. In his medical history there was no any illness and drug use. He has a regular heart rate of 100 bpm, his blood pressure was 100/75 mmHg and respiration rate was 16 breathes per minute. On physical examination, there was no symptom. Battery was seen in abdomen X-ray (figure 1). Patients were included in the polyclinic follow-up. Next day the abdomen xray showed that battery was moved forwards (figure 2).

Foreign bodyswallowing occurs usually in children and in specific high-risk groups of adults [1,2]. In the literature, there was seen ingestion of coin, battery, needle, bottle, glass etc. foreign bodies are frequently encountered in the gastrointestinal system [2-4]. While sharp objects and batteries are surgically removed, blunt objects like coins are expected to be discarded with defecation [5]. We wait thrown to battery with defecation.

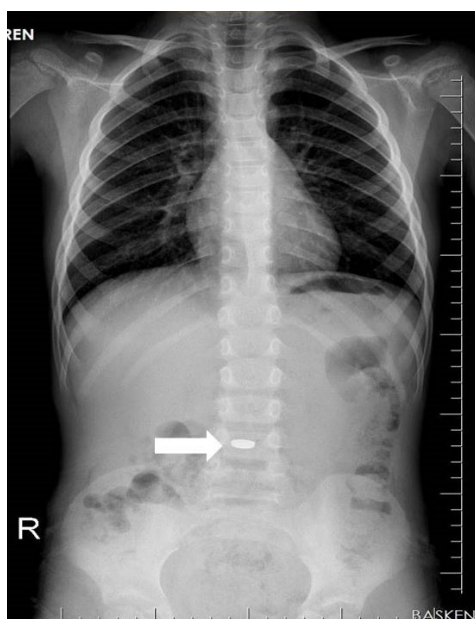


Figure 1. Battery was seen in abdomen X-ray at first day

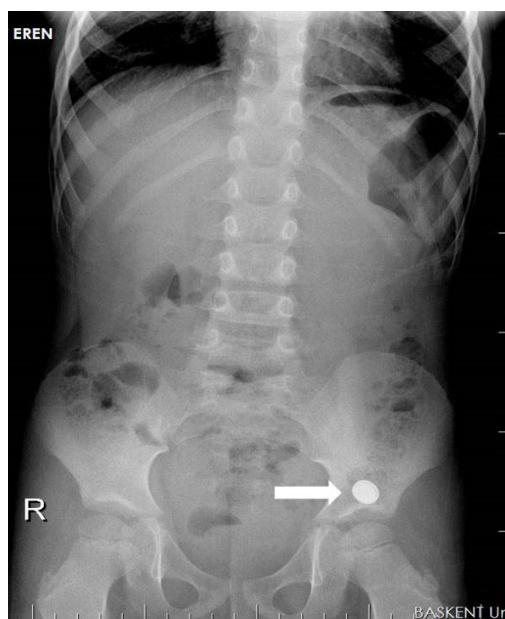


Figure 2. Battery was seen in abdomen X-ray at next day

References

1. Ozsarac M, Demircan A, Sener S. Glass Foreign Body in Soft Tissue: Possibility Of High Morbidity Due to Delayed Migration. *J Emerg Med* 2011;41(6):e125-8.
2. Zippi M, Febbraro I, De Felici I, Mattei E, Pica R, Traversa G, et al. Foreign bodies in the upper gastrointestinal tract. (Personal experience). *Clin Ter* 2007;158(4):291-5.
3. Sayhan MB, Gokdemir MT, Kavalci C. An unusual foreign body: A pendant. *J Pak Med Assoc* 2010;60(7):600.
4. Çobanoğlu U, Aşker S, Sayır F. Esophageal Foreign Bodies. *JCAM* doi: 10.4328/JCAM.2538
5. Telford JJ. Management of ingested foreign bodies. *Can J Gastroenterol* 2005;19(10):599-601.

DOI:10.4328/ECAM42

Received : 26.11.2014

Accepted : 07.12.2014

Published Online : 01.01.2015

Printed Online : 01.01.2015

Eu Clin Anal Med 2015;3(1): DOI:10.4328/ECAM42

Corresponding Author: Kayıpmaz Afşin Emre, Baskent University Faculty of Medicine, Emergency Department, Ankara, Turkey.

F: +90 312 212 68 68 • E-Mail: aekayıpmaz@yahoo.com